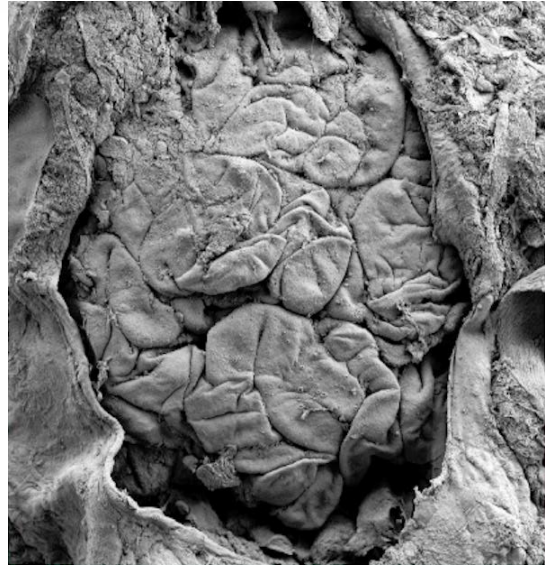
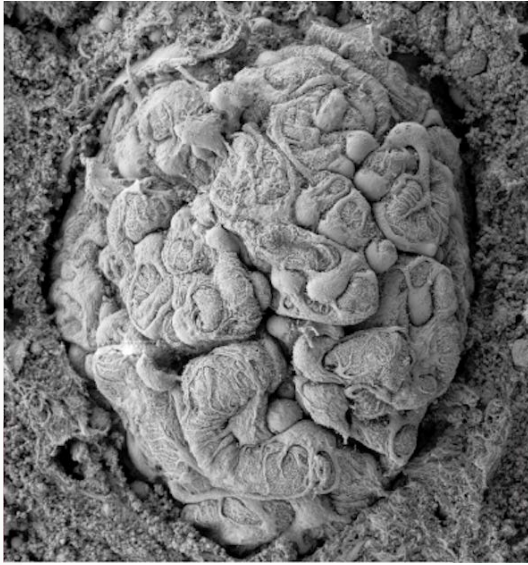


SEM – APPLICATION EXAMPLES



SEM images of a healthy renal glomerulus (left) and from a patient with advanced diabetic nephropathy (right). Original magnification: 2.5 kx.